

# Hypersensitivity Pneumonitis: A Rare Diagnosis

Sara Monteiro Cunha<sup>1</sup>, Rita Moita<sup>2</sup>, Sofia Vasconcelos<sup>1</sup>, Cláudia Neto<sup>1</sup>, Inês Azevedo<sup>2,3</sup>

Port J Pediatr 2021;52:122-6

DOI: <https://doi.org/10.25754/pjp.2021.19659>

## Abstract

Hypersensitivity pneumonitis is a pulmonary inflammatory disease that is associated with the exposition of several environmental agents in immunological susceptible individuals. It is a rare disease, and its exact prevalence remains unknown in children. A 10-year-old male hospitalized with complaints of fatigue, anorexia, abdominal pain, and dry cough subsequently developed dyspnea after mild exertion and episodes of desaturation at rest. Radiological studies and more invasive exams enabled the diagnosis of hypersensitivity pneumonitis of unknown etiology. The clinical presentation and findings in first-line diagnostic exams are non-specific. Therefore, the diagnosis of hypersensitivity pneumonitis requires a high index of suspicion. Timely diagnosis is associated with a better prognosis along with an early implementation of corticosteroid therapy and antigen avoidance, if possible.

**Keywords:** Alveolitis, Extrinsic Allergic/diagnosis; Alveolitis, Extrinsic Allergic/diagnostic imaging; Child; Diagnosis, Differential; Dyspnea/etiology

## Introduction

Hypersensitivity pneumonitis, which is also known as extrinsic allergic alveolitis, is a pulmonary syndrome characterized by the diffuse inflammation of the lung parenchyma and airways in susceptible individuals in response to inhalation to antigens to which the individual is sensitized.<sup>1</sup> The repetitive inhalation of antigens induces an exacerbated complex proinflammatory cellular and humoral immune response, with lymphocyte activation and immunoglobulin (Ig) G production. In the acute phase, B lymphocytes produce immunoglobulins (mainly IgG) that form immune complexes with

inhaled antigens.<sup>1,2</sup> Complement activation by immune complexes and cytokines production by T lymphocytes leads to the alveolar macrophages activation, which results in granulomas formation in the subacute phase and pulmonary fibrosis in the chronic phase.<sup>1</sup>

Host factors appear to be important in the hypersensitivity pneumonitis pathogenesis. The development of hypersensitivity pneumonitis in a minority of exposed individuals suggests a genetic predisposition.<sup>2</sup> The list of potential antigens includes more than 200 ubiquitous agents, the majority of which are derived from microbes, animal proteins, or low molecular weight chemical compounds.<sup>3</sup> Home is the likely causative environment in the development of hypersensitivity pneumonitis in children, mainly associated with exposure to birds, fungus, and bacteria.<sup>1,4</sup> Hypersensitivity pneumonitis occur in children regardless of their age (average age is 11 years). However, precise incidence and prevalence remain unknown, mainly due to underdiagnosis.<sup>1,2</sup> In the absence of the established diagnostic criteria, diagnosis relies on the history of exposure, precipitating antibodies to the offending antigen, clinical features, bronchoalveolar lavage and radiological and pathological findings.<sup>5</sup> There is controversy regarding the clinical phenotypes, acute, subacute, and chronic clinical presentations that are described in the literature, mostly differing on the intensity and frequency of antigen exposure as well as the onset of the symptoms.<sup>6</sup> Clinical features are nonspecific. Dyspnea on exertion, cough, weight loss, and fever are the major symptoms at presentation.<sup>1</sup> Tachypnea is consistently the most prevalent sign, but hypoxemia and crackles are also common.<sup>7</sup> Although bronchoalveolar lavage fluid findings are not pathognomonic of hypersensitivity pneumonitis, it is a sensitive tool to detect alveolitis in suspected individuals, since the marked lymphocytosis in the differential cell profile is frequently seen in hypersensitivity pneumonitis rather than in other diseases often considered in the differential diagnosis.<sup>5,8</sup>

1. Department of Pediatrics, Hospital da Senhora da Oliveira, Guimarães, Portugal

2. Department of Pediatrics, Centro Materno Pediátrico, Centro Hospitalar e Universitário de São João, Porto, Portugal

3. Gynecology, Obstetrics and Pediatrics Department, Faculdade de Medicina, Universidade do Porto, Porto, Portugal

### Corresponding Author

Sara Monteiro Cunha

<https://orcid.org/0000-0003-2758-0343>

saracunha@hospitaldeguimaraes.min-saude.pt

Department of Pediatrics, Hospital da Senhora da Oliveira, Rua dos Cutileiros, Creixomil, 4835-044 Guimarães, Portugal

Received: 10/02/2020 | Accepted: 15/10/2020 | Published online: 03/04/2021 | Published: 03/04/2021

© Author(s) (or their employer(s)) and Portuguese Journal of Pediatrics 2020. Re-use permitted under CC BY-NC. No commercial re-use.

High-resolution computed tomography plays a key role in the diagnosis of hypersensitivity pneumonitis.<sup>9</sup>

Antigen identification and avoidance remain the cornerstone of the treatment and a major determinant of prognosis.<sup>1,4</sup> However, this often represents a challenge, especially when not related to professional exposure.

## Case Report

The authors present the case of a 10-year-old Caucasian boy, born at 27 weeks of gestational age without long-term pulmonary sequela of prematurity. There was no family history of pathological relevance, except the death of his paternal grandparents due to lung cancer. The child lives in a rural area and had contact with chickens and ducks. He was observed at the emergency department with complaints of fatigue, progressive anorexia, periumbilical pain, dry cough, and low-grade fever over the past two weeks after acute bacterial tonsillitis treated with antibiotics. Physical examination was unremarkable. Complete blood count and blood chemistry were within the normal range and the chest radiograph and the electrocardiography were normal. Two days later, he was observed for recent weight loss and pleuritic chest pain. On physical examination, he presented pale skin, frequent dry cough, shallow breathing, and a respiratory rate of 40 beats per minute (bpm), with no other respiratory distress signs. Bilateral crackles were audible on pulmonary auscultation. The oropharynx examination showed inflamed tonsils with exudate. Blood and urine workup were normal and a rapid test for group A *Streptococcus* was negative. He was discharged with azithromycin for five days. Due to progressive asthenia and anorexia, medical attention was sought two days later. On physical examination, he was pale, afebrile, looking progressively ill, presented tachypnea with shallow breathing, and coughing episodes during deep breaths, with intermittent wheezing in pulmonary auscultation. An abdominal examination showed mild diffuse tenderness in the upper abdomen. He was hospitalized at the pediatric department for etiological study and clinical surveillance. The blood test showed normal complete blood count, normal kidney and liver function tests, normal arterial blood gas and negative cardiac enzymes, erythrocyte sedimentation rate and C-reactive protein. Human immunodeficiency virus testing was negative. Tuberculin skin test and gastric aspirate were negative for *Mycobacterium tuberculosis*. Serologic tests for adenovirus, cytomegalovirus, Epstein-Barr virus, *Mycoplasma pneumoniae*, *Chlamydia pneumoniae*, and

*Toxoplasma gondii* showed negative IgM antibodies. The chest radiograph (Fig. 1) showed a right lower lobe infiltrate. He started a course of ampicillin, azithromycin, and methylprednisolone. During hospitalization, episodes of sudden oxygen desaturation with perioral cyanosis and respiratory distress signs with rapid resolution during oxygen administration were seen. The chest computed tomography revealed predominantly reticular infiltrates in the lower lobes of the lungs and air bronchogram with distal atelectasis in the bases of the lung and medial segment of the middle lobe. He was discharged after six days, when asymptomatic and looking well.

One week later, he was admitted to the emergency department for anterior and pleuritic chest pain, dry cough, and tachypnea associated with periumbilical pain, so he was readmitted for further investigation. He presented progressive dyspnea, after mild exertion and episodes of tachypnoea of 40-65 cycles per minute, flaring of the nostrils and abdominal breathing, which were associated with intermittent hypoxia with a minimum peripheral oxygen saturation of 83%, and tachycardia of 140-150 bpm at rest. In these episodes, oxygen supplementation was raised up to three liters per minute with resolution within a few minutes.

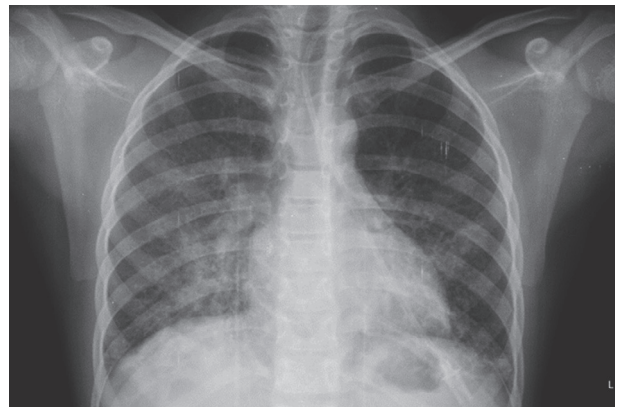


Figure 1. Chest radiograph that shows a right lower lobe infiltrate.

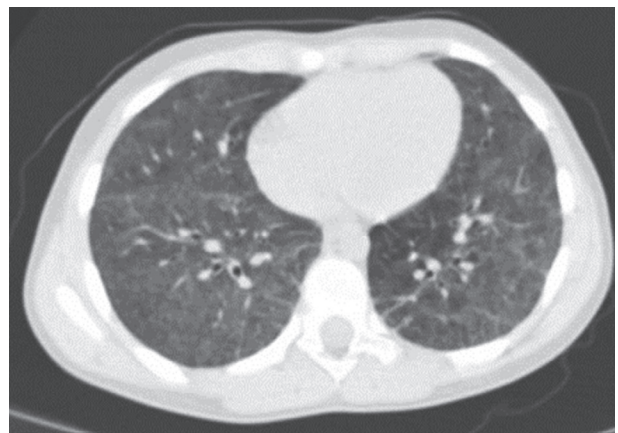


Figure 2. Chest high-resolution computed tomography showing areas of a ground glass pattern and subpleural reticular opacities.

The workup showed normal complete blood count and blood chemistry, complement, immunoglobulins, coagulation studies, cardiac enzymes, angiotensin-converting enzyme, alfa-1 antitrypsin, autoantibodies, and sweat test. Evaluation by a pediatric cardiologist excluded heart disease. A ventilation/perfusion scan revealed areas of hypoventilation in the lower lobes bilaterally and the respiratory function tests showed a severe restrictive pattern, with a forced vital capacity (FVC) of 36%. The chest high-resolution computed tomography scan (Fig. 2) showed diffuse ground-glass opacities on both pulmonary parenchyma with inferior lobes sparing and subpleural reticular opacities in the lower right lobe. These nonspecific radiological findings are highly suggestive of hypersensitivity pneumonitis. At this point, due to clinical worsening and a most likely diagnosis of hypersensitivity pneumonitis, he was transferred to a tertiary care hospital for further evaluation. Since there was no temporal relationship between the symptoms and animal contact nor bedroom makeover, a careful environmental history was obtained and it revealed that the symptoms might be related to exposure to a public swimming pool in the summertime. His mother reported identical but less severe symptoms in the previous summer after having been exposed to the same public swimming pool, which had disappeared spontaneously when he returned to school.

Bronchoalveolar lavage fluid revealed a predominance of lymphocytes (67.4%), especially CD8 lymphocytes, resulting in a CD4/CD8 ratio of 0.35. *Aspergillus fumigatus* serum precipitins were positive. Therefore, hypersensitivity pneumonitis diagnosis was made, probably related to the public swimming pool facilities. He started a high dose prednisolone with prompt clinical response and remained asymptomatic after steroids weaning and strict avoidance of exposure to the swimming pool. The child has been asymptomatic after a three-year follow-up and has both respiratory function tests and alveolocapillary diffusion by a carbon monoxide test within the normal ranges.

## Discussion

Childhood interstitial lung disease (chILD) is a broad term for a group of rare lung diseases found in infants, children, and teenagers. These disorders share common features and are associated with impaired gas exchange and abnormal imaging features due to the remodeling of the lung interstitium and distal airspaces.<sup>7,10</sup> However, as some childhood interstitial lung diseases may involve other parts of the lung, rather than the interstitium

alone, diffuse lung disease is considered as the most accurate term.<sup>7</sup> Diffuse lung disease is a heterogeneous group of lung disorders associated with high morbidity and mortality that include, among many other rare lung developmental and genetic disorders, hypersensitivity pneumonitis.<sup>10</sup>

The authors present this case not only because of its rarity in the pediatric population but also for the difficulty of establishing a hypersensitivity pneumonitis diagnosis. As is often the case, children may be initially misdiagnosed as having pneumonia and be treated with antibiotics, as symptoms, physical examination, and first-line diagnostic exams are nonspecific. In this case, the authors conducted further investigation because of atypical symptoms for pneumonia, such as hypoxia episodes. Indeed, the evidence of hypoxemia is often the first abnormality to raise concern for a diagnosis of interstitial lung diseases.<sup>11</sup>

The clinical evaluation and further workup usually rule out genetic disorders, systemic diseases, sarcoidosis, hemosiderosis, aspiration syndrome, and cardiac disorders. The high-resolution computed tomography scan was crucial in directing the investigation toward an interstitial pulmonary disease. High-resolution computed tomography features that are highly suggestive of hypersensitivity pneumonitis may include ground-glass opacification, centrilobular nodules, decreased attenuation and vascularity, and a lack of lower zone predominance of abnormalities. Hypersensitivity pneumonitis, alveolar proteinosis, and neuroendocrine cell hyperplasia of infancy are the few interstitial disorders where the computed tomography pattern may be completely diagnostic, but even in those diseases, the diagnosis is usually supported by other diagnostic tests.<sup>11</sup>

Bronchoalveolar lavage fluid findings may support the possible diagnosis of hypersensitivity pneumonitis in the presence of a marked alveolar lymphocytosis in a patient with interstitial lung disease of unknown origin.<sup>7</sup> Besides marked lymphocytosis in the bronchoalveolar lavage fluid, a low ratio of lymphocyte CD4/CD8 supported hypersensitivity pneumonitis over sarcoidosis, a pulmonary disease often considered in the differential diagnosis.<sup>8</sup>

Positive serum precipitins are a noteworthy predictor of hypersensitivity pneumonitis, but this disease cannot be ruled based on the presence of a specific antibody nor ruled out in its absence, as serum precipitins are just a marker of exposure.<sup>7,12</sup> The mainstay treatment of hypersensitivity pneumonitis is the avoidance of the causative antigen. However, complete removal may not always be possible as antigen may not be

identified or because its removal may imply major lifestyle changes.<sup>2,13</sup> Therefore, the long-term prognosis of hypersensitivity pneumonitis is a cause of concern as it relies on antigen identification and avoidance. In our patient, an exhaustive environmental history suggested a possible relation to exposure to antigens at the outdoor public swimming pool facility. In fact, the exposure to hot tub baths has been recently associated with a new disorder - the hot tube disorder - that could occur in other recreational water facilities, such as swimming pools, as waters may be easily contaminated by nontuberculous mycobacteria, which are highly resistant to the disinfectants used in swimming pools and spas.<sup>3,14</sup>

We highlight the importance of a high index of suspicion and detailed environmental history for a prompt diagnosis of hypersensitivity pneumonitis, as its diagnosis in children is often late and when early diagnosed may be completely reversible.<sup>4,15</sup>

Upon the suspicion of interstitial lung disease, children must be evaluated at specialized referral centers with expertise in the diagnosis and management of childhood interstitial lung diseases and be evaluated by a multidisciplinary team.<sup>7</sup> Although confirming a diagnosis of childhood interstitial lung diseases requires a pediatric pulmonologist, a general pediatrician plays a significant role in recognizing the need for further evaluation in

children with concerning symptoms and their referral to avoid unnecessary diagnostic procedures.

#### WHAT THIS CASE REPORT ADDS

- Pediatric hypersensitivity pneumonitis is a rare condition and it is often misdiagnosed.
- Careful environmental history plays an important role in the management of this disorder.
- Dyspnea on exertion, cough, weight loss, and fever are the most common symptoms.
- Marked alveolar lymphocytosis in the bronchoalveolar lavage fluid may support the diagnosis.
- Avoidance of the causative antigen is the cornerstone of the treatment.

#### Conflicts of Interest

The authors declare that there were no conflicts of interest in conducting this work.

#### Funding Sources

There were no external funding sources for the realization of this paper.

#### Provenance and peer review

Not commissioned; externally peer reviewed

#### Consent for publication

Consent for publication was obtained.

#### Confidentiality of data

The authors declare that they have followed the protocols of their work center on the publication of patient data.

#### References

1. Silva SR, Carvalho I, Romariz J, Costa H, Praça F. Pneumonite de hipersensibilidade em idade pediátrica - revisão teórica e algoritmo de atuação. *Saúde Infant* 2013;35:69-74.
2. Spagnolo P, Rossi G, Cavazza A, Bonifazi M, Paladini I, Bonella F, et al. Hypersensitivity pneumonitis: A comprehensive review. *J Investig Allergol Clin Immunol* 2015;25:237-50.
3. Nogueira R, Melo N, Novais e Bastos H, Martins N, Delgado L, Morais A, et al. Hypersensitivity pneumonitis: Antigen diversity and disease implications. *Pulmonology* 2019;25:97-108. doi: 10.1016/j.pulmoe.2018.07.003.
4. Selman M, Pardo A, King TE Jr. Hypersensitivity pneumonitis: Insights in diagnosis and pathobiology. *Am J Respir Crit Care Med* 2012;186:314-24. doi: 10.1164/rccm.201203-0513CI.
5. King TE. Diagnosis of hypersensitivity pneumonitis (extrinsic allergic alveolitis) [accessed 31 January 2020]. Available at: <https://www.uptodate.com>
6. Alves P, Simões M, Esperto H, Meira E, Ferreira E, Batista M, et al. Hypersensitivity pneumonitis: A clinical case. *J Med Cases* 2012;3:155-9.
7. Kurland G, Deterding RR, Hagood JS, Young LR, Brody AS, Castile RG, et al. An official American Thoracic Society clinical practice guideline: Classification, evaluation, and management of childhood interstitial lung disease in infancy. *Am J Respir Crit Care Med* 2013;188:376-94. doi: 10.1164/rccm.201305-0923ST.
8. King TE. Role of bronchoalveolar lavage in diagnosis of interstitial lung disease. [accessed 31 January 2020]. Available at: <https://www.uptodate.com>
9. Cardoso J, Carvalho I. The value of family history in the diagnosis of hypersensitivity pneumonitis in children. *J Bras Pneumol* 2014;40:183-7. doi: 10.1590/s1806-37132014000200013.
10. Soares JJ, Deutsch GH, Moore PE, Fazili MF, Austin ED, Brown RF, et al. Childhood interstitial lung diseases: An 18-year retrospective analysis. *Pediatrics* 2013;132: 684-91. doi: 10.1542/peds.2013-1780.
11. Bush A, Cunningham S, de Blic J, Barbato A, Clement A, Epaud R, et al. European protocols for the diagnosis and initial treatment of interstitial lung disease in children. *Thorax* 2015;70:1078-84. doi: 10.1136/thoraxjnl-2015-207349.
12. Lacasse Y, Cormier Y. Hypersensitivity pneumonitis. *Orphanet J Rare Dis* 2006; 3;1:25. doi: 10.1186/1750-1172-1-25.
13. Sforza GGR, Marinou A. Hypersensitivity pneumonitis: A complex lung disease. *Clin Mol Allergy* 2017;15:6. doi: 10.1186/s12948-017-0062-7.
14. Fjallbrant H, Akerstrom M, Svensson E, Andersson E. Hot

tub lung: An occupational hazard. Eur Respir Rev 2013;22:88-90. doi: 10.1183/09059180.00002312.  
15. Griese M, Haug M, Hartl D, Teusch V, Glöckner-Pagel J,

Brasch F, et al. Hypersensitivity pneumonitis: Lessons for diagnosis and treatment of a rare entity in children. Orphanet J Rare Dis 2013;8:121. doi: 10.1186/1750-1172-8-121.

### Pneumonite de Hipersensibilidade: Um Diagnóstico Raro

#### Resumo:

A pneumonite de hipersensibilidade é uma doença pulmonar inflamatória relacionada com a exposição a vários agentes ambientais em indivíduos geneticamente suscetíveis. É uma patologia rara e a sua prevalência na população pediátrica ainda permanece desconhecida. Uma criança de 10 anos, sexo masculino, internada por anorexia, fadiga, dor abdominal e tosse seca desenvolveu no internamento dispneia para pequenos esforços e episódios de dessaturação em repouso. O estudo complementar efetuado permitiu o diagnóstico de pneumonite de hipersensibilidade de

etiologia desconhecida. A apresentação clínica e os achados nos exames complementares de primeira linha são inespecíficos. Assim, o diagnóstico de pneumonite de hipersensibilidade requer um elevado índice de suspeição. O diagnóstico atempado, um tratamento precoce com corticoterapia e a evicção antigénica, quando possível, estão associados a melhor prognóstico.

Palavras-Chave: Alveolite Alérgica Extrínseca/diagnóstico; Alveolite Alérgica Extrínseca/diagnóstico por imagem; Criança; Diagnóstico Diferencial; Dispneia/etiologia