

Meningitis in a Small Infant. When Something is Not What it Seems

Gonçalo Padeira¹, Carla Conceição², José Pedro Vieira³, Maria João Brito¹

Port J Pediatr 2018;49:369-70

DOI: <https://doi.org/10.25754/pjp.2018.12235>

Six month old baby admitted with fever of 39.2°C, irregular breathing and convulsive status epilepticus. A brain computed tomography and subsequently a brain magnetic resonance (Figs. 1, 2 and 3) revealed ischaemic stroke involving the territories of the anterior, middle and posterior cerebral arteries to the left and part of the territory of the perforating branches to the right, with leptomeningeal captures, predominantly basal and heterogeneous signal of the cerebrospinal fluid (CSF). The anterior fontanelle was hypertensive. A lumbar puncture revealed cloudy liquor with 64 cells/μL with a predominance of lymphocytes, glucose 20 mg/dL, proteins 158.6 mg/dL. The baby was medicated with ceftriaxone and vancomycin without improvement. The child's parents were drug addicted and lived in a Lisbon neighbourhood with a high incidence of tuberculosis. The baby was not vaccinated against tuberculosis.¹ Blood

and CSF cultures were sterile. Given the social and epidemiological history, the characteristics of the CSF and negative cultures, antituberculous drugs were started. The direct test for mycobacteria in the gastric juice and a chain reaction of the polymerase in the CSF identified *Mycobacterium tuberculosis*, subsequently confirmed in culture test. Evolution was towards right spastic hemiplegia, predominantly brachial and epilepsy.

The typical presentation of tuberculous meningitis is classically insidious with manifestations that appear over weeks or less frequently it manifests as hydrocephaly with no apparent cause. Encephalitis or pyogenic meningitis-like as occurred in this case, is rare but possible. Hypoglycorrhachia and high proteinorrhachia in the CSF are also present in bacterial meningitis, but a meningitis of the base associated to risk factors for tuberculosis should make us suspect this diagnosis.²⁻⁴

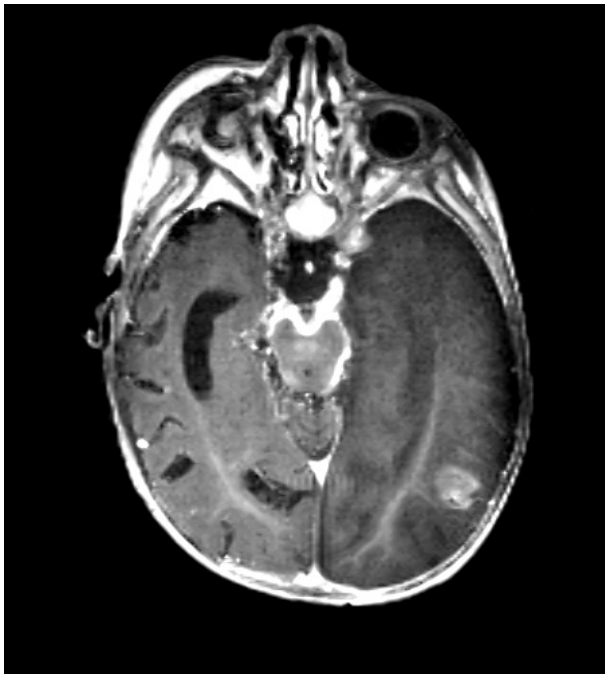


Figure 1. Brain magnetic resonance of the patient three days after admission. Axial T1 with gadolinium – thick and heterogeneous perimesencephalic cap and in the common oculomotor nerves.

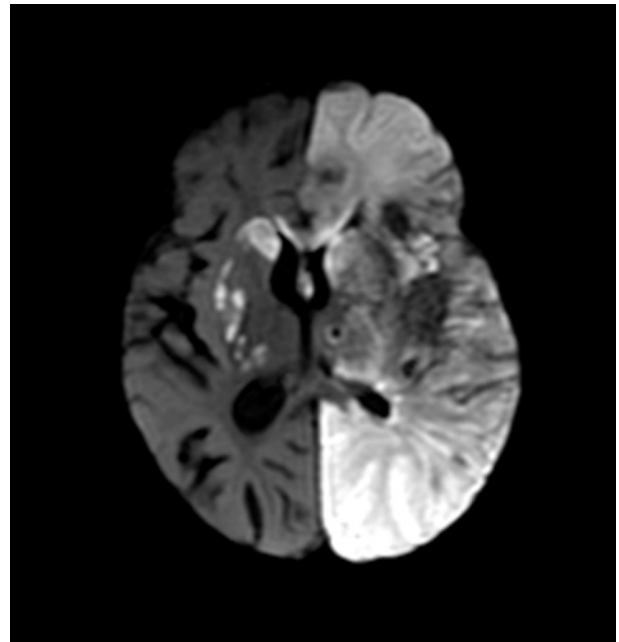


Figure 2. Brain magnetic resonance of the patient three days after admission. Axial diffusion – restriction to diffusion in the cerebral hemisphere and nuclei of the base to the left and more focal in the nuclei of the base to the right.

1. Infectious Diseases Unit, Paediatrics Department, Hospital Dona Estefânia, Central Lisbon Hospital, Lisbon, Portugal

2. Neuroimaging Department, Hospital Dona Estefânia, Central Lisbon Hospital, Lisbon, Portugal

3. Neurology Unit, Paediatrics Department, Hospital Dona Estefânia, Central Lisbon Hospital, Lisbon, Portugal

Corresponding Author

Gonçalo Padeira

goncalo_padeira@hotmail.com

Infectious Diseases Unit, Pediatrics Department, Hospital Dona Estefânia, Central Lisbon Hospital, R. Jacinta Marto, 1169-045 Lisbon, Portugal

Received: 27/06/2017 | Accepted: 12/04/2018

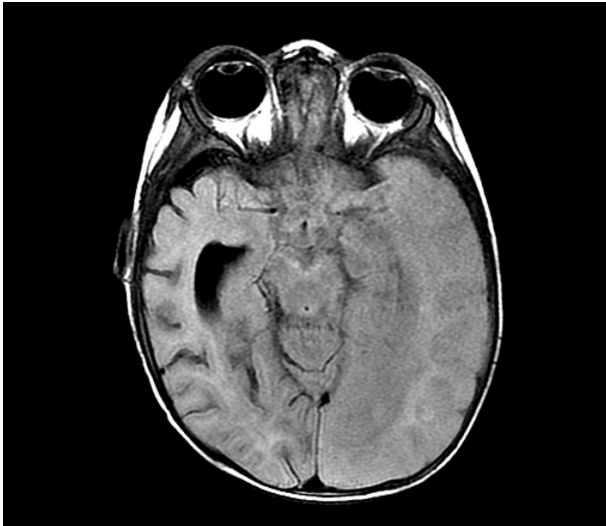


Figure 3. Brain magnetic resonance of the patient three days after admission. Axial FLAIR – hypersignal of the cisterns of the base, dedifferentiation between the cortex and the white matter to the left.

Keywords: Infant; Tuberculosis, Meningeal/diagnosis

WHAT THIS REPORT ADDS

- Acute encephalopathic meningitis is not always caused by the classic bacterial agents (*Neisseria meningitidis*, *Streptococcus pneumoniae* and *Haemophilus influenzae*), specially in small infants.
- Reinforces the importance of the social and epidemiological context in tuberculosis.
- Reinforces the role of the vaccination against tuberculosis in the groups at risk.
- Evokes the diagnosis of tuberculous meningitis and the need for early diagnosis in order to minimise in good time in order to minimise morbidity and mortality.

Conflicts of Interest

The authors declare that there were no conflicts of interest in conducting this work.

Funding Sources

There were no external funding sources for the realization of this paper.

Protection of human and animal subjects

The authors declare that the procedures followed were in accordance with the regulations of the relevant clinical research ethics committee and with those of the Code of Ethics of the World Medical Association (Declaration of Helsinki).

Confidentiality of data

The authors declare that they have followed the protocols of their work centre on the publication of patient data.

References

1. Directorate-General for Health. Strategy of vaccination against tuberculosis with the BCG vaccine. Standard no.. 06/2016 (29/06/2016). Lisbon: DGS; 2016.
2. Perez-Velez CM, Marais BJ. Tuberculosis in children. *N Engl J Med* 2012;367:348-61.
3. Dheda K, Barry CE, Maartens G. Tuberculosis. *Lancet* 2016;387:1211-26.
4. Thwaites GE, Van Toorn R, Schoeman J. Tuberculous meningitis: More questions, still too few answers. *Lancet Neurol* 2013;12:999-1010.